Wir machen mobil

Anatomie des Kniegelenkes

swiss olympic medical center

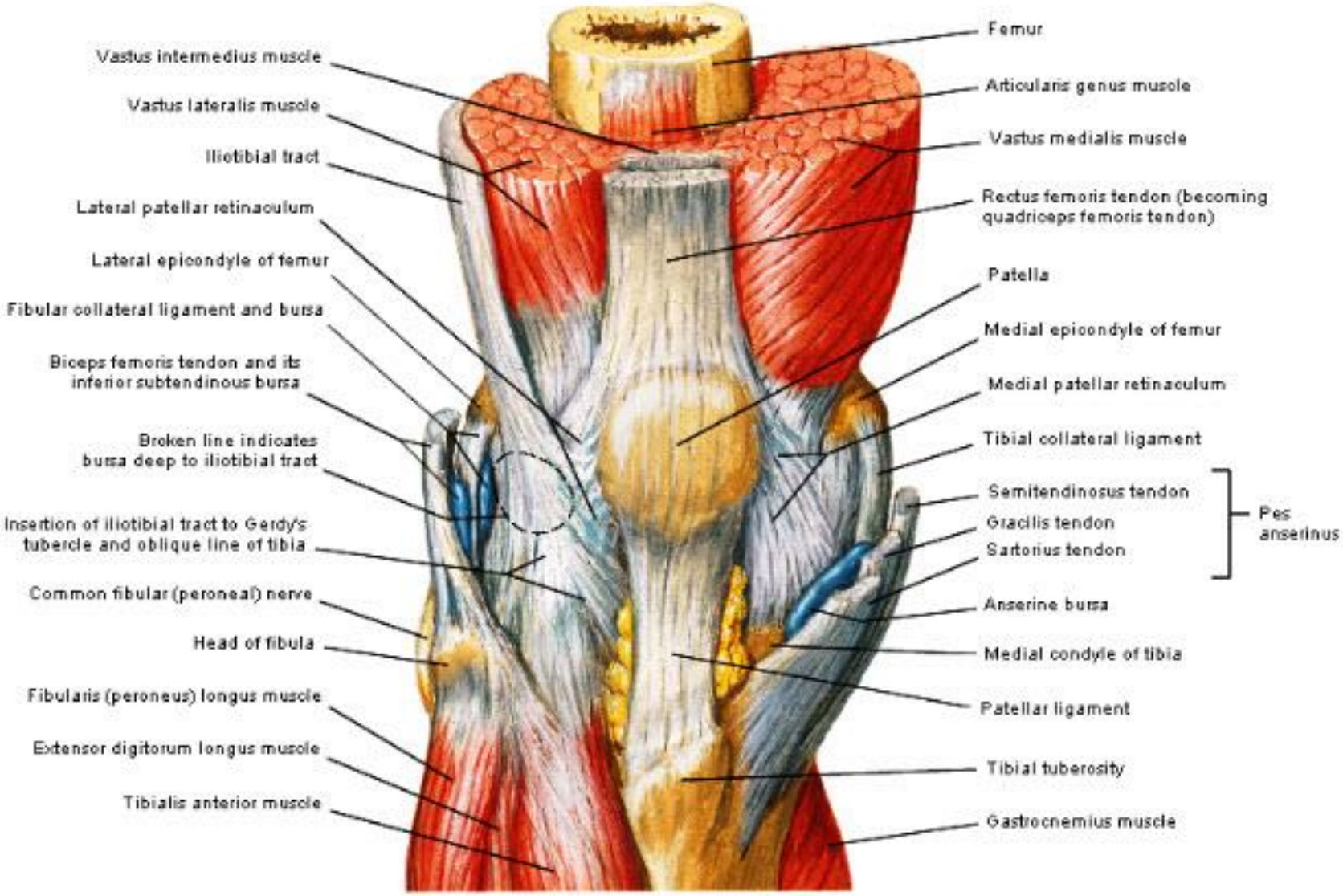
Vastus intermedius muscle
Vastus lateralis muscle
Iliotibial tract
Lateral patellar retinaculum
Lateral epicondyle of femur
Fibular collateral ligament and bursa
Biceps femoris tendon and its inferior subtendinous bursa
Broken line indicates bursa deep to iliotibial tract
Insertion of iliotibial tract to Gerdy's tubercle and oblique line of tibia
Common fibular (peroneal) nerve
Head of fibula
Fibularis (peroneus) longus muscle
Extensor digitorum longus muscle
Tibialis anterior muscle
Femur
Articularis genus muscle
Vastus medialis muscle
Rectus femoris tendon (becoming quadriceps femoris tendon)
Patella
Medial epicondyle of femur
Medial patellar retinaculum
Tibial collateral ligament
Semitendinosus tendon
Gracilis tendon
Sartorius tendon
Pes anserinus
Anserine bursa
Medial condyle of tibia
Patellar ligament
Tibial tuberosity
Gastrocnemius muscle

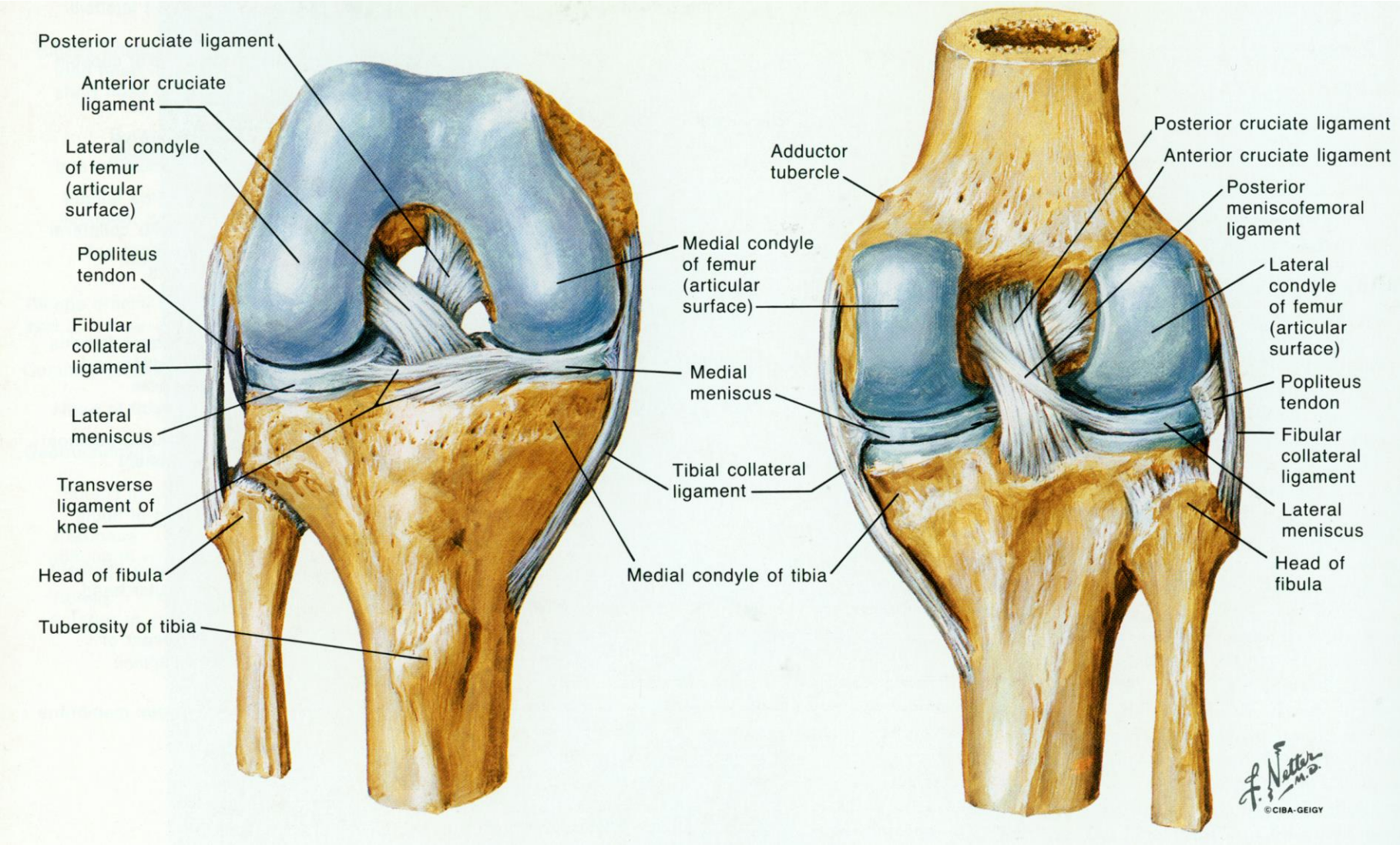
Posterior cruciate ligament
Anterior cruciate ligament
Lateral condyle of femur (articular surface)
Popliteus tendon
Fibular collateral ligament
Lateral meniscus
Transverse ligament of knee
Head of fibula
Tuberosity of tibia
Medial condyle of femur (articular surface)
Medial meniscus
Tibial collateral ligament
Medial condyle of tibia
Adductor tubercle
Posterior cruciate ligament
Anterior cruciate ligament
Posterior meniscofemoral ligament
Lateral condyle of femur (articular surface)
Popliteus tendon
Fibular collateral ligament
Lateral meniscus
Head of fibula
F. Netter M.D.
©CIBA-GEIGY

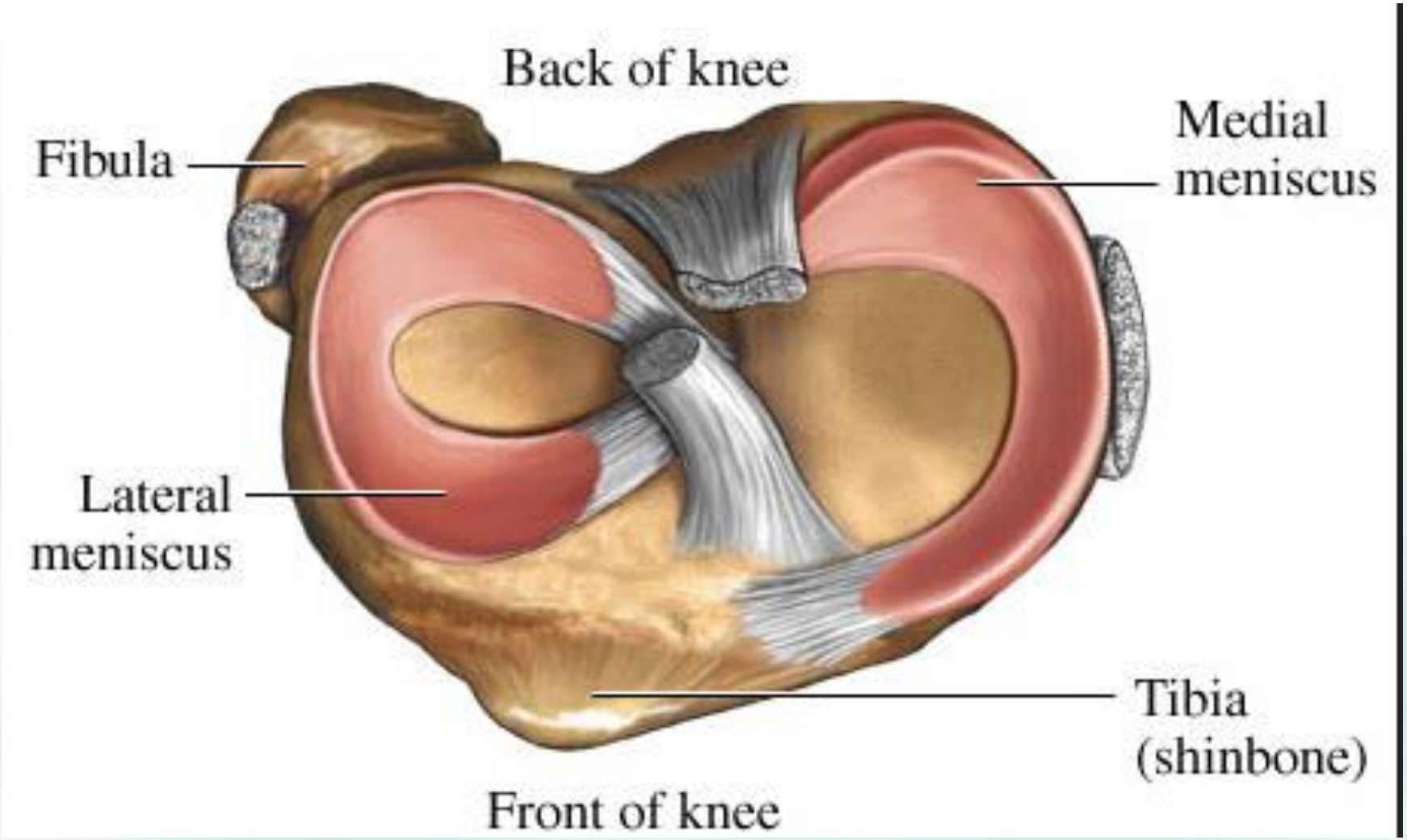
Back of knee
Fibula
Medial meniscus
Lateral meniscus
Tibia (shinbone)
Front of knee